Letters to Editor

Airway challenges in laryngotracheoplasty with Montgomery T-tube for subglottic stenosis

Sir,

Most anaesthesiologists do not have the opportunity to provide anaesthesia care for patients either coming for Montgomery T-tube insertion or reconstruction of the trachea with Montgomery T-tube *in situ*.[1,2] Tracheal stenosis following tracheostomy is mostly the result of abnormal wound healing with excess granulation tissue formation around the tracheal stoma site.[3] The reported incidence of tracheal stenosis following tracheostomy and laryngotracheal intubation ranges from 0.6% to 21 %.[4]

The Montgomery T-tube [Figure 1] is a device used as a combined tracheal stent and also as an airway following laryngotracheal surgery. We hereby describe the anaesthetic management of a 33-year-old male patient posted for laryngotracheoplasty with Montgomery T-tube insertion for subglottic stenosis. This patient had undergone surgical tracheostomy 4 months ago for prolonged mechanical ventilation following intracranial haemorrhage. Two attempts at decannulation had failed. Flexible video laryngoscopy had revealed granulation tissue above the stoma completely obstructing the airway [Figure 2]. He was conscious, alert, obeying commands and breathing normally through the tracheostomy tube with oxygen saturation of 94%–96% on room air. In the operating room ECG, Pulse Oximeter, NIBP monitors were connected. After obtaining intravenous (IV) access, the patient was adequately pre-oxygenated. The patient received IV glycopyrrolate 0.2 mg, midazolam 2 mg, fentanyl 100 µg, titrated doses of propofol (total 80 mg) and atracurium 30 mg. The tracheostomy tube was replaced with No. 6 cuffed flexometallic endotracheal (ET) tube and secured. Anaesthesia was maintained with O_2:air mixture, 6%–7% desflurane (0.8–1 MAC) with combination of IV infusions of propofol 0.1–0.2 mg/kg/min and dexmedetomidine 0.3–0.5 mcg/kg/h. A combination of both inhalational (desflurane) and IV anaesthetics were used to overcome the risk of awareness as there were periods of apnoea associated with repeated removal and reinsertion of the endotracheal tube (ETT), and thus interrupting ventilation. Intermittent boluses of atracurium were used to maintain adequate muscle relaxation. Direct rigid laryngoscopy done by ENT surgeon revealed circumferential granulation tissue below the subglottis at the level of first tracheal ring completely occluding the airway.

Surgical plan was total excision of the granuloma both through the glottis and tracheostomy stoma and reconstruction of the trachea with Montgomery T-tube [Figure 3]. This necessitated the endotracheal tube to be frequently removed and reinserted to provide optimal surgical exposure while ensuring haemodynamic stability and adequate ventilation. Other issues of concern during this phase included risk of airway fires, which was reduced by usage of Coblator™ for excision of the granuloma, and lighter planes of anaesthesia. After complete excision, the



Figure 1: Montgomery T-tube

Figure 2: Granulation tissue totally occluding the lumen of trachea

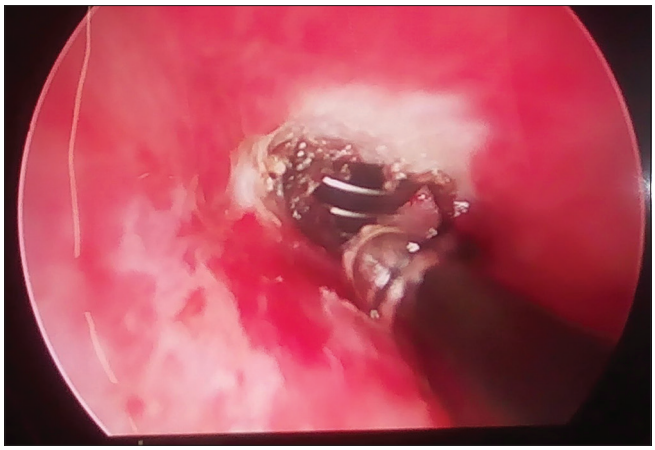

Figure 3: Coblator-assisted excision of granulation tissue

flexometallic tube was removed, and a Proseal™ laryngeal mask airway (LMA) No. 3 was placed. A No. 10 T-tube (Invotec™) was placed and confirmed by fibreoptic bronchoscope, followed by successful completion of laryngotracheoplasty. At the conclusion of the procedure, neuromuscular blockade was antagonised and Proseal™ LMA was removed on return of adequate spontaneous breathing. The extra-tracheal part of the T-tube was closed using a spigot and the patient was allowed to breathe spontaneously.

There were various challenges posed during the surgical procedure which included (a) maintenance of adequate ventilation to avoid hypoxia and hypercarbia, (b) maintenance of adequate depth of anaesthesia and (c) maintenance of haemodynamic stability. Hypoxia and hypercarbia were managed or prevented by titrating the ventilatory parameters such as increasing the respiratory rate and ensuring adequate tidal ventilation by adopting pressure control mode of ventilation. The apnoeic periods were kept brief and limited to the period when the ETT needed to be removed and reinserted during the initial phases of the surgical procedure. In the later stages, the ETT was replaced with the Proseal™ LMA to facilitate uninterrupted ventilation. Inhalational agent (desflurane) was supplemented with injection dexmedetomidine infusion, and with propofol infusion whenever endotracheal tube had to be removed during the surgical procedure.

The management of patients for T-tube insertion or those with T-tube *in situ* poses difficulty in controlled ventilation as T-tubes are not provided with standard connectors to fit with anaesthesia breathing circuits, and the proximal open end causes loss of inspired gases. In surgeries involving the upper airway, sharing of surgical field with the airway is an additional challenge.

We used a No. 3 Proseal™ LMA during the laryngotracheoplasty and T-tube insertion to provide ample surgical site exposure. Fresh gas leak through the stoma during laryngotracheoplasty was managed using 100% O_2 and intermittent approximation of the stoma by the surgeon. After the insertion of T-tube, proper ventilation was re-established by closing the extra-luminal arm of the T-tube with a spigot and allowing the intratracheal portion for gas exchange through the LMA. The presence of LMA also facilitated the confirmation of proper placement of the T-tube by flexible bronchoscopy.

Declaration of patient consent

The authors certify that they have obtained all appropriate patient consent forms. In the form the patient(s) has/have given his/her/their consent for his/her/their images and other clinical information to be reported in the journal. The patients understand that their names and initials will not be published and due efforts will be made to conceal their identity, but anonymity cannot be guaranteed.

Acknowledgement

The authors would like to thank the patient and his family for permitting to publish the case report.

Financial support and sponsorship

Nil.

Conflicts of interest

There are no conflicts of interest.

Dhanveer J Shetty, MN Chidananda Swamy, Shantanu Tandon[1]

Departments of Anaesthesiology and [1]ENT, Sakra World Hospital, Bengaluru, Karnataka, India

Address for correspondence:
Dr. MN Chidananda Swamy,
Department of Anaesthesiology, Sakra World Hospital,
Bengaluru - 560 103, Karnataka, India.
E-mail: chidakala2002@yahoo.co.in

REFERENCES

1. Guha A, Mostafa SM, Kendall JB. The Montgomery T-tube: Anaesthetic problems and solutions. Br J Anaesth 2001;87:787-90.
2. Park JS, Kwon YS, Lee S, Yon JH, Kim DW. Airway management using laryngeal mask airway in insertion of the Montgomery tracheal tube for subglottic stenosis - A case report. Korean J Anesthesiol 2010;59 Suppl:S33-6.
3. Zias N, Chroneou A, Tabba MK, Gonzalez AV, Gray AW, Lamb CR, *et al.* Post tracheostomy and post intubation tracheal stenosis: Report of 31 cases and review of the literature. BMC Pulm Med 2008;8:18.
4. Sarper A, Ayten A, Eser I, Ozbudak O, Demircan A. Tracheal stenosis after tracheostomy or intubation: Review with special regard to cause and management. Tex Heart Inst J 2005;32:154-8.

This is an open access article distributed under the terms of the Creative Commons Attribution-NonCommercial-ShareAlike 3.0 License, which allows others to remix, tweak, and build upon the work non-commercially, as long as the author is credited and the new creations are licensed under the identical terms.

Access this article online	
Quick response code	Website: www.ijaweb.org
	DOI: 10.4103/ija.IJA_302_17

How to cite this article: Shetty DJ, Chidananda Swamy MN, Tandon S. Airway challenges in laryngotracheoplasty with Montgomery T-tube for subglottic stenosis. Indian J Anaesth 2018;62:145-7.

© 2018 Indian Journal of Anaesthesia | Published by Wolters Kluwer - Medknow